



Paraurethral cyst with multiple stones: A Case report

Fatma Noorwali^{a,*}, Ethar Alboloshi^b

^a Department of Obstetrics and Gynecology, King Abdulaziz Medical City- Western Region, Ministry of National Guard Health Affairs, Jeddah, Saudi Arabia

^b College of Medicine, King Saud Bin Abdulaziz University for Health Sciences, Jeddah, Saudi Arabia

ARTICLE INFO

Keywords:

Paraurethral cyst
Paraurethral stone
Periurethral diverticulum
Vaginal cyst

ABSTRACT

Paraurethral cyst is a rare cystic condition that presents in the distal wall of the vagina. Stone formation in paraurethral cyst is rare (Blaivas et al., 2004) [1]. We report a Case of a 64-year-old multiparous, post-menopausal woman who presented with complaints of a hard swelling in the vagina and heaviness for 15 years. Cystourethroscopy and excision of the paraurethral cyst was planned. The cyst was opened, and multiple small stones along with the cyst wall were removed. The ureteroscopy was repeated, and the urethra was intact after cyst removal. She was seen a month later, and the patient was voiding well.

Introduction

Paraurethral cyst is a cystic condition that presents in the wall of the vagina close to the urethra. The prevalence of paraurethral cyst among females is 1–6%, and it is typically detected in patients aged 20–60 years.¹ A retrospective chart review was conducted by examining the database of a urology and urogynecology practice, which contained the cases of 1950 females.² A periurethral mass was detected in 74 patients, which was less than 4% of the sample, between 1994 and 2002.¹ The presenting symptoms of patients with periurethral masses varied and included overactive bladder, incontinence, and dyspareunia.¹ A thorough evaluation of the patients' cases was performed and included their history, physical examination, timing of urination, uroflow, and post void residual urine measurement, with cystoscopy and video urodynamic testing for patients with lower urinary tract symptoms. Some patients also underwent magnetic resonance imaging (MRI), computed tomography (CT), or double-balloon urethrography.¹ The identified differential diagnosis of the periurethral cysts included urethral diverticulum and vaginal cyst.²

Case report

This is a case of a 64-year-old multiparous, post-menopausal woman who presented with complaints of a hard swelling/mass and heaviness in the vagina for the past 15 years. Her only relevant medical history was perineal tear which occurred during her prior deliveries. The patient had no urinary complaints and no recurrent urinary tract infections. Upon examination, the mass was 3 × 2 cm with hard, tiny structures inside.

Upon pressing on the cyst, nothing came out of the urethral meatus. There was no tenderness, no redness, and no change in the cyst over-time. A pelvic examination suggested a provisional diagnosis of paraurethral cyst filled with hard masses suspected to be stones. An ultrasound of the genitourinary system was conducted, which detected no stones in the upper urinary system. The differential diagnoses were Gartner's cyst, stones in the diverticulum, or implanted dermoid after birth trauma. A pelvic ultrasound was conducted to exclude other stones within the urinary system. Surgery was planned consisting of cystourethroscopy and excision of the paraurethral cyst. A cystoscopy was conducted to exclude urethral caruncle and diverticulum. The cystoscopy revealed a normal bladder and urethra with no connection between the cyst and the urethra. In the operation room, the patient was placed in the lithotomy position. A Foley catheter was inserted, and the vaginal epithelium above the cyst was opened with Foley catheter in situ. The cyst was opened as shown in Fig. 1, and multiple small stones were removed as shown in Fig. 2. The stone composition was found to be 50% Ammonium Hydrogen Urate and 50% Carbonate Apatite (Dahllite). The cyst wall was removed, and the area was enclosed with in-layers, as was the vaginal epithelium. The pathology of the paraurethral cyst consisted of single small piece of grayish brown ductal structure measured 0.6 × 0.6 × 0.3 cm and lined by squamous epithelium. The ureteroscopy was repeated, and found that the urethra was intact as shown in Fig. 3. The patient wasn't discharged with a Foleys catheter. The postoperative period remained uneventful, and the patient was discharged the following day. She was observed at the clinic a month later, and the patient was symptom-free and was voiding well. At that time, she was also counseled about the risk of urethral fistula.

* Corresponding author. Jeddah, Saudi Arabia.

E-mail address: fnoorwali30@yahoo.com (F. Noorwali).

<https://doi.org/10.1016/j.eucr.2021.101774>

Received 15 June 2021; Received in revised form 7 July 2021; Accepted 9 July 2021

Available online 9 July 2021

2214-4420/© 2021 The Authors.

Published by Elsevier Inc.

This is an open access article under the CC BY-NC-ND license

(<http://creativecommons.org/licenses/by-nc-nd/4.0/>).

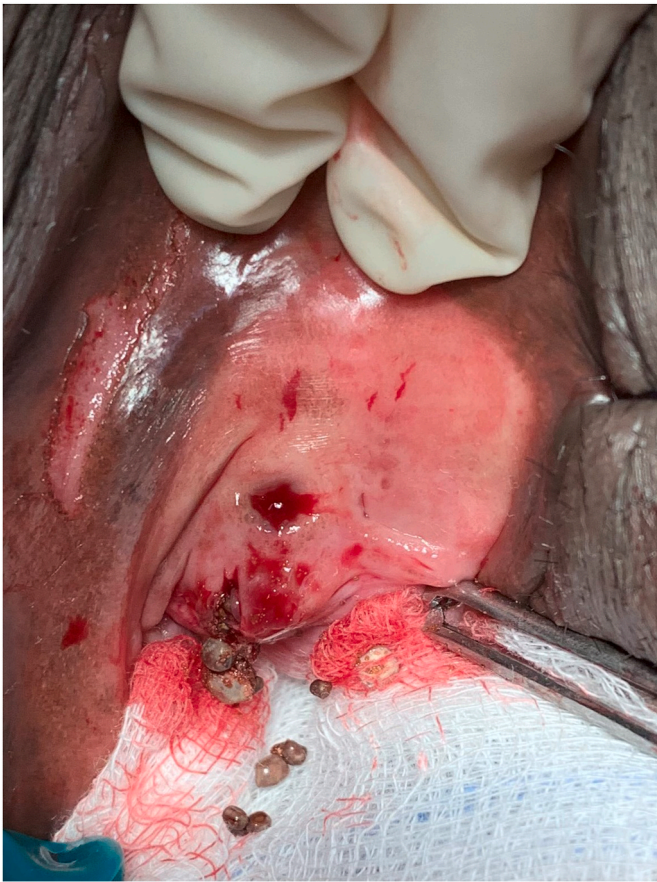

Fig. 1. Opening of the cyst with stones extraction.



Fig. 2. The extracted stones.

Discussion

Paraurethral cysts are benign cystic lesions that may be accompanied by various complications, but stone formation is rare.² About one out of 200 females presents with vaginal cysts, but not all cases are reported, so the exact number is greater.³ Vaginal cysts are formed either from the vaginal tissues or from the urethra and the tissues surrounding it.⁴ The various types of cysts include Müllerian cysts, epidermal inclusion cysts, Gartner's duct cysts, Bartholin's gland cysts, and endometriotic cysts. However, cysts of urethral and paraurethral origin are rare.⁴ A paraurethral duct cyst is located at the base of the distal urethra, and its histology is stratified squamous.⁴ Symptoms of vaginal cysts include discomfort, vaginal heaviness, and urinary symptoms, such as urinary incontinence or obstructive voiding.⁴ Physical examination and cystourethroscopy are sufficient to diagnose paraurethral cysts, and a transvaginal ultrasound may play a role in ruling out urethral diverticula.⁵ Paraurethral cyst is managed by surgical extraction of the cyst.⁵

The difference in presentation and treatment of this case from previously published case report are few significant points. There are few published case reports about paraurethral cyst with stones, and they are not recent. The presentation of our case is different because the patient's only complaint was heaviness in the vagina with no urinary complaints unlike all published case reports. Also, the stone components in this case are different from the stone components of previously published case reports. Due to the few cases of paraurethral cyst with multiple stones seen in urogynecology practice, there is no consensus on its management, but this case report will hopefully add to the few published case reports to help guide when future cases are encountered by physicians.

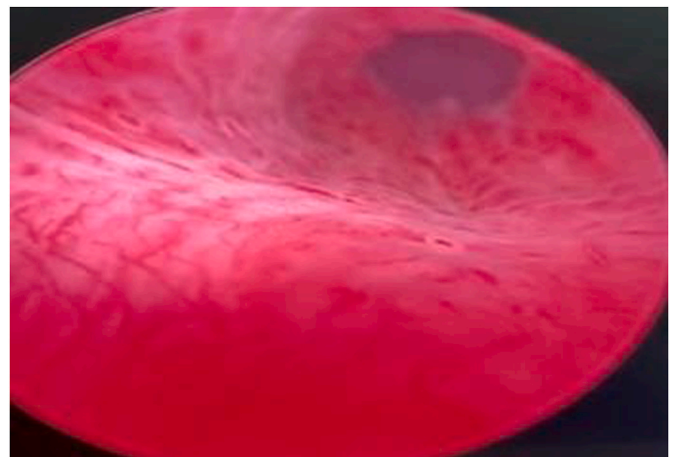


Fig. 3. Intact posterior urethral wall after cyst extraction (ureteroscopic image).

Conclusion

A paraurethral cyst is a benign swelling around the urinary meatus, which is covered by the vaginal epithelium, and the distal urethra, which is characterized by a lack of collapse upon pressing. Paraurethral cyst stones can be diagnosed via ultrasound, which is performed to detect stones in the paraurethral cyst and to rule out the presence of any stones in the urinary system. Paraurethral cyst stones can be managed successfully through cystourethroscopy and excision of the paraurethral cyst. A cystoscope is performed to rule out urethral diverticula. This can

result in complications such as fistula and infections; however, our patient fortunately had a positive outcome with no complications.

Financial support and sponsorship

None to declare.

Declaration of competing interest

There are no conflicts of interest.

References

1. Blaivas JG, Flisser AJ, Bleustein CB, Panagopoulos G. Periarethral masses: etiology and diagnosis in a large series of women. *ACOG*. 2004;103(5, Part 1):842–847.
2. Prakash G. Paraurethral cyst with multiple stones: a rare Case report. *Urol Ann*. December 2016;8(4):509–511. <https://doi.org/10.4103/0974-7796.192088>.
3. Smith RP, Netter FH. *Netter's Obstetrics and Gynecology*. Philadelphia, PA: Saunders/Elsevier; 2008.
4. Eilber KS, Raz S. Benign cystic lesions of the vagina: a literature review. *J Urol*. 2003; 170(3):717–722.
5. Köse O, Aydemir H, Metin O, Budak S, Sonbahar A, Adsan Ö. Experiences with the management of paraurethral cysts in adult women. *Cent European J Urol*. 2013; 477–480.